

Skin conditions that mimic child abuse: a Quiz!

Ciara Earley 18th April 2016

Why this quiz is important!

- We really do get referrals for some of these conditions!
- It's fun at the end of the day!

Mistakes do occur

- 50 children over a 10year study period that were given an alternate diagnosis
- Most common “mistake” was confusing impetigo with cigarette burns
- Several children were from low SE backgrounds and had risk factors for abuse or neglect

- Wheeler DM et al **Mistakes in diagnosing non-accidental injury:10 years' experience** *BMJ* vol 296 April 1988

1. First day in child care, young carer concerned about these bruises on the child's back. What are these lesions called?

Birthmarks: Congenital dermal melanocytosis

- > 90% SE Asians, 80 % other Asians, Africans, 50-70% Hispanics, < 10% in whites
- May appear after birth in first few weeks
- Fade by 3yr may persist longer
- Looks like bruises to the untrained eye
- No swelling or tenderness
- Unchanged over days

2. This 3 yr old boy was referred by GP with perianal warts, for assessment of sexual abuse? What is this condition?

**•*Sex Transm Infect.* 2003
October; 79(5): 424.**

Birthmarks: Perianal verrucous epidermal naevus

- Seen at birth but may be delayed up to puberty
- Close set warty papules coalesce to keratotic plaques-linear distribution
- In perianal area may mimic viral warts
- Stable nature, linear distribution and HPE can be used to differentiate

- The Journal of Paediatrics 2009 154: 306

3. **A teacher is worried about these recurrent red marks on this boy. They fade after a few days to brown bruise like lesions. What are these lesions? What is a diagnostic sign?**

emedicine.medscape.com

Cutaneous mastocytosis

- Any number, any size, yellow tan to red brown
- Pruritic macules, papules, nodules, plaques, blisters, bullae
- More on trunk than limbs, spares face, scalp, palms and soles
- **Darier sign** - surrounding wheal and erythema on rubbing
- Systemic symptoms - flushing, headache, dyspnoea, rhinorrhoea, wheezing, vomiting, diarrhoea, syncope- exposure to certain drugs or foods
- 75% occur in infancy and childhood and resolve by puberty

5. 6 d female with seizures, hyper pigmented lesions and bruises, maternal grandmother known to CPS. Mum single 18 yr old.

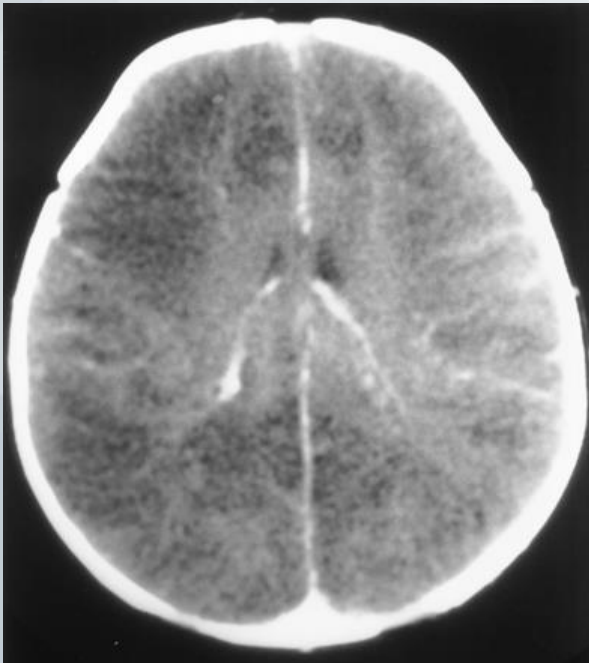
Melbourne
Children's

Excellence in
clinical care,
research and
education



Murdoch
Childrens
Research
Institute





- Cerebral infarcts and cerebral oedema on CT brain
 - Baby has bilateral retinal haemorrhages
 - Is it Shaken baby syndrome?
 - What else could it be?
-
- Pediatrics 1997; 11: 4 pp e6

Genetic disorders

Incontinentia pigmenti

- Genodermatosis, X linked dominant, variable expression
- Lesions form a pattern along Blaschko's lines
- Stage 1- first 6 w, inflammatory phase - vesicles on erythema- may look like burns, impetigo, herpes simplex or epidermolysis bullosa-raised WCC and eosinophils
- Stage 2 -a few mo - verrucous plaques
- Stage 3 - most characteristic – localized/ extensive, whorls – trunk, streaks on extremities, may fade during childhood/adolescence, flares of vesiculopustular and verrucous lesions occur
- Stage 4 - 14% and 28% have hypopigmented and atrophic streaks in adulthood
- CNS changes, eye cataracts, strabismus, retinal vascular changes etc

5 year old girl referred from ED with recurrent injuries, lacerations and history of minor trauma. In the care of father, family known to DHHS previously. Mum history of psych disorder? diagnosis



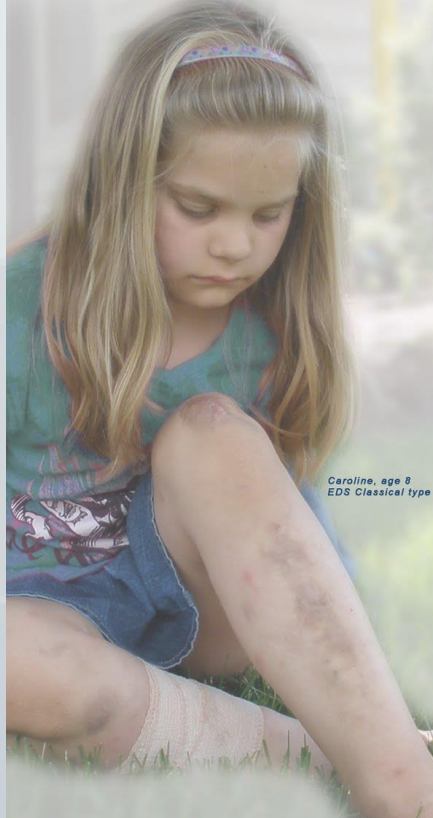Melbourne Children's
Excellence in clinical care, research and education



Murdoch Childrens Research Institute



This is not Child Abuse It's Ehlers-Danlos Syndrome



If your child bruises
or scars more often
or more severely than
other children...

Or they have wounds
that heal slowly, gape
open, frequent stitches
that don't hold, flexible
joints that cause pain
and/or dislocate,
muscle cramps, heart
problems, soft, velvety
and stretchy skin...

When you know
something isn't right,
when the signs are too
hard to ignore,
it's time to ask your
pediatrician,
family physician or
a qualified geneticist
about
Ehlers-Danlos Syndrome.

Ehlers-Danlos Syndrome

It could be the piece of the puzzle that you're missing.

Visit www.ehlersdanlosnetwork.org
or call (262) 514-2851
For understanding, support and hope.



©2010 Ehlers-Danlos Syndrome Network C.A.R.E.S. Inc.

Melbourne
Children's
Excellence in
clinical care,
research and
education



Murdoch
Children's
Research
Institute



Ehlers Danlos Syndrome

- Group of disorders (6 subtypes), genetic defect in collagen and connective tissue synthesis
- Type of EDS depends on how collagen metabolism has been affected
- Signs and sx include skin fragility, bruising and haematomas after trivial injuries, internal collagen defects, hypermobility

7. What is this practice called? What type of injuries does it cause?

Melbourne
Children's

Excellence in
clinical care,
research and
education



Murdoch
Childrens
Research
Institute



Cultural practices - coining

- SE Asian “Cao Gio”-scratch the wind
- For fever, headache, chills
- Oiled skin is rubbed firmly with edge of coin causing linear bruises
- Severe burns have been reported when oil on the skin caught fire

What cultural/beauty treatment is this? What injuries can it cause?

**Melbourne
Children's**

Excellence in
clinical care,
research and
education



**Murdoch
Childrens
Research
Institute**



Cultural practices: cupping

- Middle Eastern, E European, Asian, S American
- Circular bruises/petechiae/burns on back
- Cotton soaked in alcohol placed in cup, ignited and removed
- Cup placed on skin
- Heated air in cup contracts and sucks up skin, burning and bruising the skin

15. This 2 w baby (of Turkish background) is brought in with seizures and large areas of blistering rash. Electrolytes reveals Na of 165 mmol/L. What could have caused this presentation?



Cultural practices - salting

- Application of salt to skin-Turkish custom to improve complexion
- Can result in epidermolysis (looks like burns) and hypernatremia

21. What is this cultural practice called and what injury does it produce?

**Melbourne
Children's**

Excellence in
clinical care,
research and
education



**Murdoch
Childrens
Research
Institute**



Cultural practices - moxibustion



- SE Asian
- Burning of moxa (mugwort or *Artemesia vulgaris*) or yarn on skin
- Pattern of small discrete circular burns can look like cigarette burns

8. A young child with ulcers on soles of feet, multiple scars on limbs, tongue and lips, deformed fingers, and bilateral deformities from old fractures. Concerns about long term abuse? What condition does this child have?



Melbourne Children's
Excellence in clinical care, research and education



Murdoch Childrens Research Institute



Genetic disorders

Congenital insensitivity to pain

- Presents from neonatal period to 10 y
- Tongue/lip biting, multiple skin wounds, fractures, deformities, autoamputation of fingers/toes
- Decubitus ulcers, osteomyelitis
- Fever from anhidrosis
- Variable sensory loss more distal
- Loss of pain sensation, occasionally temperature, vibration, proprioception sensation
- ID may be present

10. **5 month old with vomiting, poor feeding, lethargy and periorbital bruising. Worked up with CT (subdural haemorrhage) and bone scan (multiple areas of increased uptake in metaphysis). Referred for a forensic assessment for abusive trauma? What condition do you suspect? What test would you do?**

Neuroblastoma

- Urine catecholamines-VMA and HVA
- Most common extracranial solid tumour of childhood
- 2/3rds have metastatic disease on presentation
- Presentation with periorbital ecchymosis with or without proptosis (from orbital metastasis) may mimic abuse
- Bone metastasis is multiple symmetric and metaphyseal
- CT brain can show necrosis, haemorrhage and calcification

11. 13 yr old says she developed these red lumps after a fight in school when she was kicked on her shins, knees and ankles. What are these lesions?

Erythema nodosum

- Idiopathic, infections (TB, strep, mycoplasma), systemic (sarcoid, IBD), drugs (sulphas, OC)
- In children infection is most common cause
- >in females
- Hypersensitivity-panniculitis inflammation of SC fat
- Smooth, red, painful nodules, 2-6 cm, coalesce, continue to appear for 3-6 w
- Anterior surface of legs, thighs, and forearms
- Fever, arthralgia may occur
- As it heals may become yellowish and look like bruises may desquamate
- Infection - heal in 7 w may last up to 18 w, idiopathic - last 6 mo

12. 8 mo old baby is teething, otherwise well. Taken to GP for nodular, red, indurated, swelling on both his cheeks, mum puzzled! GP thinks they are bruises. What is this condition called?

The Atlas of Emergency Medicine

Melbourne
Children's

Excellence in
clinical care,
research and
education



Murdoch
Children's
Research
Institute



Popsicle (cold) panniculitis

- Aunt had given him popsicles to help with teething pain
- Benign cold induced subcutaneous fat necrosis on cheeks of young infants
- Occurs 1-3 days after cold exposure
- Localised, indurated nodules, ill defined margins, cold, and painful
- Self limiting disorder, symptomatic relief

13 month old child presented to childcare with multiple bruises, several areas of the body ,notification made to Child Protection



Melbourne
Children's
Excellence in
clinical care,
research and
education



Murdoch
Childrens
Research
Institute



What would you do? ?Investigations



Melbourne Children's
Excellence in clinical care, research and education



Murdoch Childrens Research Institute



ITP , platelet count 12

- Isolated thrombocytopenia
- Usually viral trigger
- Management controversial, most resolve within 6 months
- Usually primary but can be secondary to other causes eg drug induced

**14. These conditions are sometimes at the onset thought to be from abuse.
What are they called ?**

Hypersensitivity/Vasculitis

- Acute haemorrhagic oedema of infancy (picture on the left)
- Henoch Schonlein purpura (right)

16. 7 yr history of recurring rash is in emergency with mum in a cubicle, triage nurse does not see any rash, heard to cry out with pain and shortly after on exam this bruise is seen on his arm. What does he have?

Hypersensitivity/Vasculitis

Urticarial vasculitis

- *Eruption associated with burning pain*
- Generalized/localized wheals or plaques with central clearing
- Petechiae within lesion and resolve with bruises or post inflammatory hyperpigmentation
- Lasts > 24 hr in a fixed location unlike urticaria which migrates in minutes to hours
- Photosensitivity, arthralgia, angioedema, fever, dyspnoea, abdominal pain, pleural/pericardial effusions
- Most idiopathic
- Drugs: penicillin, sulphas, fluoxetine, NSAID
- Autoimmune disease SLE, Sjogren's
- Malignancies
- Infections: Hep B, Hep C, IM

**4 year old child presenting with “blood in undies”,
scratches and touches at her vagina frequently.
Concerns around paternal uncle who lives in the
house**



**Melbourne
Children's**
Excellence in
clinical care,
research and
education



**Murdoch
Childrens
Research
Institute**



Lichen Sclerosis

- Shiny white plaques and papules with a semi-translucent appearance
- Purpura and telangiectasia, excoriation and blistering
- Males and females affected
- Symptoms: Bleeding, pruritis, vulval soreness
- Can be mistaken for abuse

Jenny C et al **Genital Lichen Sclerosus Mistaken for Child Sexual Abuse** *Pediatrics* 1989;83:597-599

Young SJ et al **Lichen Sclerosus, genital trauma and child sexual abuse** *Aust Fam Physician* 1993;22:729

**2 year old girl “always has red vagina when she returns home from Dad’s house”.
Acrimonious parental separation**



Melbourne Children's
Excellence in clinical care, research and education



Murdoch Childrens Research Institute



vulvovaginitis

- “The red vagina”
- Prepubertal susceptibility (2-7 years)
- Loss of maternal oestrogens over 1st years
 - ❖ Flat labia majora, thin labia minora,
 - ❖ Loss of glycogen epithelium becomes thin and atrophic
 - ❖ Loss of acidity and reduced resistance to infection

Garden A.S. **Vulvovaginitis and other common childhood gynaecological conditions** *Arch Dis Educ Pract Ed*
2011,96:73-78

Vulvovaginitis

- Contributing factors : anatomy , poor hygiene
- Presentation varied, symptoms may be severe
- Various organisms isolated
- Candida unusual in toilet trained girls

- Jaquier A et al **Vulvovaginitis:clinical features,aetiology and microbiology of the genital tract** *Arch Dis Child*,1999.81(1):p64-67
- Emans S, **Vulvovaginal problems in the prepubertal child**, in *Paediatric and Adolescent Gynaecology*, S Emans, M Laufer and D Goldstein editors. 2005 Lippincott Williams & Wilkins p 83-120

Genital Ulceration

- 12 year old girl
- 3/7 history of genital ulceration
- Systemic symptoms
- Commenced on po keflex by GP
- Denied sexual contact
- ? investigations

Investigations

- Herpes PCR –ve including multiplex
- M/C/S –ve
- ↑inflammatory markers
- EBV serology IgG +ve, IgM –ve
- Syphilis serology –ve
- Stool positive for salmonella

Causes of ulceration

- Reiters syndrome :arthritis, conjunctivitis, urethritis /cervicitis and mucocutaneous lesions
- Bechets: Recurrent oral and genital ulcers,meningoencephalitis,cutaneous vasculitis and synovitis
- Enteric infection : Shigella
- Described in Salmonella typhi
- Steven Johnson, drug eruptions , impetigo

17. What do these conditions have in common? The child on the right was gardening the day before.

www.uptodate.com/contents/differential-diagnosis-of-suspected-child-abuse

Hypersensitivity/Vasculitis Phytophotodermatitis

Limes/Lemons/Oranges
Celery
Grasses
Parsley
Parsnips
Sagebrush
Goldenrod
Chrysanthemum
Ragweed
Cocklebur
Tobacco
Figs
Garlic
Hot peppers



Phytophotodermatitis

- Temporal exposure with phototoxic furocumarins in some plants and UVA 320-380 nm = phototoxic skin eruption
- Begins 24 h after exposure peaks at 48 -72 h
- Burning sensation - erythema and blisters, look like burns, followed by pigmentation, may look like bruises
- Prior sensitisation is not required
- Bizarre patterns may be seen
- Has been mistaken for abuse when finger impressions patterns are seen as carer touches child after handling the plant material

18. Child care reports 6 mo child (mum chemical dependent) with tender red swellings on toes. What is this condition? What is the cause?

emedicine.medscape.com

Melbourne
Children's

Excellence in
clinical care,
research and
education



Murdoch
Children's
Research
Institute



Pernio/Chilblains

- 12-24 hr after exposure to non freezing, damp, cold
- Single/multiple, red purplish, oedematous lesions, turn yellowish brown, with desquamation
- Intense pain, burning, itching
- Toes/fingers, dorsum of proximal phalanges, pinnae, cheeks, nose, thighs
- Circulation normal
- Excessive cold, neglect, anorexia nervosa, presence of cryoproteins, SLE, presence of anticardiolipin/antiphospholipid antibodies

22. What are the lesions in the picture on the left and on the right?

Impetigo v Cigarette burns

- Impetigo, yellow crust, different sized, spreading
- Cigarette burns may vary from circular bullae to deep punched out craters with raised edges, 8mm in size, centre of burn deepest.
- If same cigarette is used the lesions will be the same size

23. When a child in nappies presents with burns to the buttocks/genital area what history must you obtain?



Pediatrics 2001; 107:1 178

Melbourne Children's
Excellence in clinical care, research and education



Murdoch Childrens Research Institute



Laxative-Senna induced dermatitis

- Senna can cause severe nappy rash and in overdose situations in children wearing nappies can cause a blistering rash which looks like scalds
- Can be used by defence, so document exclusion of laxative use in children with scalds in buttock/genital area

25. This child who has substantiated Hx of neglect has patchy hair loss. Hairs easily plucked. Is it traumatic alopecia? What else could it be?

Loose Anagen syndrome

- > in girls 2-5 yr
- anagen hairs, easily and painlessly plucked,
- Hair is thin, dry, dull and unmanageable
- does not grow beyond nape of neck
- child otherwise healthy, rest of body hair not involved, teeth and nails normal.
- DD: Alopecia areata, Trichotillomania, traction alopecia, telogen effluvium, tinea capitis

3 year old boy, "sore , itchy bottom". S/B GP concerns about sexual abuse



Melbourne
Children's
Excellence in
clinical care,
research and
education



Murdoch
Childrens
Research
Institute



Perianal streptococcus

- Sharply demarcated redness, itch and painful on defecation
- TX 14/7 with penicillin

13 year old boy under GA for procedure, anaesthetist concerned re lesions on anus, notifs Child Protection



Melbourne
Children's
Excellence in
clinical care,
research and
education



Murdoch
Children's
Research
Institute



Crohn's disease

- Swelling, fissures, ulceration and skin tags affecting the vulval and perivulvar regions
 - May present with clitoral oedema
 - G.I. Symptoms may be minimal
 - Vulvar inflammation may be the only clinical manifestation
-
- Corbett S et al **Vulvar inflammation as the only clinical manifestation of Crohn's disease in an 8 year old girl** *Pediatrics* 2010;125:e1518-1522

Summary

- It's important to diagnose and suspect cases of child abuse but as important not to misdiagnose!
- If unsure, look again or consult